



## International Journal of Case Reports (ISSN:2572-8776)



# Manual physical therapy clears adhesive bowel obstruction and strictures in a patient with Crohn's disease

<sup>1</sup> Leonard B Weinstock, <sup>2</sup> Janey S A Pratt, <sup>3</sup> Lawrence Wurn, <sup>4</sup> Sharon Hepburn,

<sup>1</sup> Associate Professor of Clinical Medicine and Surgery, Washington University School of Medicine; Specialists in Gastroenterology, LLC, St. Louis, MO 63141, United States; <sup>2</sup> Clinical Associate Professor of Surgery, Stanford University School of Medicine, Palo Alto, CA 94035, United States; <sup>3</sup> Director of Clinical Research, Clear Passage Therapies, Gainesville, FL; <sup>4</sup> Clinical Director, Clear Passage Therapies, St. Louis, MO

### ABSTRACT

A woman with Crohn's disease with prior resection presented with a one-year history of persistent abdominal pain. The small bowel follow-through radiograph demonstrated the presence of two strictures in the small intestine due to adhesive scarring. Opting for conservative management, the patient underwent a specialized manual physical therapy regimen. Following treatment, the patient experienced significant decrease of abdominal pain and improved biomechanical function. Radiologic imaging revealed complete resolution of both strictures. Manual physical therapy may be a viable non-operative option to manage small bowel strictures or obstruction.

**Keywords:** Manual physical therapy, adhesive bowel obstruction and strictures, Crohn's disease

### \*Correspondence to Author:

Lawrence Wurn

Director of Clinical Research, Clear Passage Therapies, Gainesville, FL

### How to cite this article:

Leonard B Weinstock, Janey S A Pratt, Lawrence Wurn, Sharon Hepburn. Manual physical therapy clears adhesive bowel obstruction and strictures in a patient with Crohn's disease. International Journal of Case Reports, 2018 2:19

 eSciPub  
eSciPub LLC, Houston, TX USA.  
Website: <http://escipub.com/>

## BACKGROUND

Intraperitoneal adhesions carry significant morbidity, accounting for the majority of mechanical small bowel obstructions (SBO). Current management for SBO includes intravenous fluids, often use of nasogastric suction, and close observation. This is followed by surgical lysis of adhesions if the obstruction fails to resolve. Repeated surgery in Crohn's disease can lead to short bowel syndrome.

Intraperitoneal adhesions are pathologic strands of fibrous scar tissue that form between the peritoneum, omentum, and bowel loops. Adhesions are an undesirable corollary of the normal healing response to peritoneal tissue damage incurred by surgery, radiation, infection, or trauma.[1,2] Adhesions can significantly alter spatial anatomy, resulting in obstruction and technically challenging surgeries in the future.[3,4] Adhesions account for 50 to 80% of mechanical small bowel obstruction (SBO).[5,6] Among SBO secondary to adhesions, it is estimated that 85% are caused by intra-abdominal surgery, 10% follow peritonitis, and 5% are due to an idiopathic or congenital etiology.[7]

Mechanical SBO occurs when there is a partial or complete intraluminal blockage of content flow.[8] Luminal blockage leads to proximal dilation of the bowel with decompressive collapse distal to the obstruction. If severe, the bowel may become strangulated with subsequent ischemia, necrosis, and perforation leading to a significantly elevated risk of mortality.[9,10] Current guidelines outlining the management of SBO are based on the etiology, severity, and location.[11,12,13] Consensus evidence-based management of SBO remains elusive, with high variability among clinical practices.

We describe a patient with two strictures in the small bowel secondary to postoperative adhesions in which the strictures and adhesions were successfully treated non-

surgically using an innovative, manual physiotherapy regimen.

## CASE PRESENTATION

A 37 year old G3P2 female presented to her gastroenterologist with a one-year history of persistent abdominal pain. She had been diagnosed with Crohn's disease 19 years earlier, resulting in resection of six inches of her terminal ileum. She reported being entirely symptom-free until one year prior when she suddenly began experiencing intermittent, dull and aching pain (4/10) in her right lower quadrant. Pain occasionally transitioned to sharp, shooting sensations (8/10) with radiation into the right upper quadrant of her abdomen and lumbar area. She endorsed postprandial exacerbation of her symptoms with some high fiber foods. On her worst days, the patient reported a functional decline to near 50% in performing activities of daily living. Review of symptoms was positive for dyspareunia and urinary frequency.

Past medical history was remarkable for hypertension and Crohn's disease. Surgical history was significant for perirectal cyst removal five years prior, C-section with adhesiolysis 10 years prior, appendectomy with bowel resection 19 years prior, and inguinal hernia repair over 30 years before. Abnormal physical exam findings included mild abdominal distention and right lower quadrant tenderness to palpation.

## INVESTIGATIONS

Colonoscopy performed shortly after her initial presentation demonstrated normal mucosa and diameter throughout the colon, anastomosis, and neoterminal ileum. One of the authors (LW, Gastroenterology) reviewed the photographs from this exam and agreed with the findings. A small-bowel follow-through revealed two strictures in separate areas of the bowel (Figures 1A and 2A).

## DIFFERENTIAL DIAGNOSIS

Differential diagnosis of obstructions in Crohn's disease includes fibrotic strictures,

inflammatory tissue in the wall of the intestine, inflammatory mass surrounding the intestine, adenocarcinoma, lymphoma, adhesions surrounding the intestine, and extrinsic adhesions pulling the intestine into a sharp turn.

## TREATMENT

The patient underwent a six-week prednisone challenge to determine if her jejunal narrowing was due to inflammation rather than scar tissue. She experienced no alleviation of symptoms during this period, therefore was subsequently referred for surgical consultation. A surgeon recommended resection of the stricture. Preferring to pursue non-operative management, she sought out alternative therapy via an Internet search. She came across a manual physiotherapy known as the Clear Passage Approach (CPA) which has previously been shown to decrease abdominopelvic adhesions [34-37].

Five months after the small-bowel follow-through, she initiated treatment with CPA. This method is an intensive, whole-body, manual physical therapy regimen designed to decrease and reverse the bonding of collagenous crosslinks which are at the core of adhesion formation. The amount of force and time the force was applied to each area was maintained within the tolerance of the subject. In total, the patient participated in twenty hours of CPA over the span of four consecutive days. The patient was further instructed in self-treatment techniques as well as body and spinal mechanics, core stabilization, posture correction, pelvic floor strengthening, urge suppression, and functional ADL training. All procedures were performed in accordance with guidelines of the American Physical Therapy Association.

## OUTCOME AND FOLLOW-UP

Following treatment, the patient reported complete decrease in right lower quadrant and lumbar pain and tenderness. She experienced a decreased frequency of night-time urination. Pain associated with bowel movements also

subsided; however, her stools had become less regular. Functional status improved, with patient able to walk for longer periods. Furthermore, the patient demonstrated objective improvements in spinal range of motion and biomechanics, with a marked decrease in tenderness to palpation. Repeat small-bowel follow-through following therapy demonstrated resolution of both narrowed areas (Figures 1B and 2B).

## DISCUSSION

Conservative, non-operative management can be a viable approach to managing low-risk, symptomatic SBO, however, success varies with the etiology.[14] In the setting of adhesive partial SBO, a conservative approach has been shown to be successful in 65 to 80% of cases, with a relatively low overall incidence of ischemia ranging from 3 to 6%.[15-19] While this approach is more tenuous in patients with complete SBO, some studies still report non-operative management to be successful in 41 to 73% of these cases.[20] In all cases, failure of non-operative management quickly portends surgical intervention per current guidelines.

In non-emergent cases, this is less than ideal for a multitude of reasons that include prolonged hospital stays, increased costs, and more frequent 30-day readmissions.[21] Furthermore, intra-abdominal surgery is well-established as the most common etiology of adhesions, with subsequent interventions associated with increased risk.[22] Long-term benefits from this surgical approach are also unconvincing, with many patients re-experiencing abdominal pain only one year after surgery, often due to worsening or *de novo* formation of additional adhesions.[23-25]

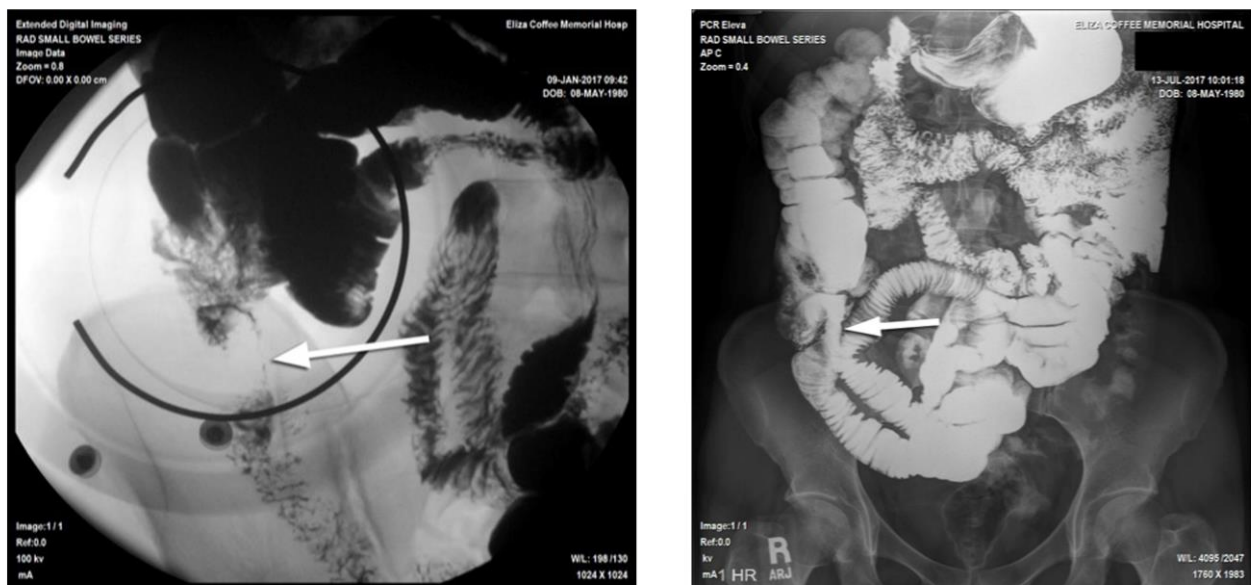
In the present case, we reported the use of an innovative soft tissue therapy to treat a female with a one-year history of abdominal pain caused by two small-bowel narrowed areas secondary to surgically-induced adhesions. After 20 hours of intensive, individualized manual physical therapy performed over four consecutive days with a focus on deforming

and detaching adhesive crosslinks, this patient experienced near complete resolution of her chronic pain that coincided with radiographic resolution of both of the previously identified small intestine strictures. The clinical findings suggest that external adhesions were affecting the diameter of the neoterminal.

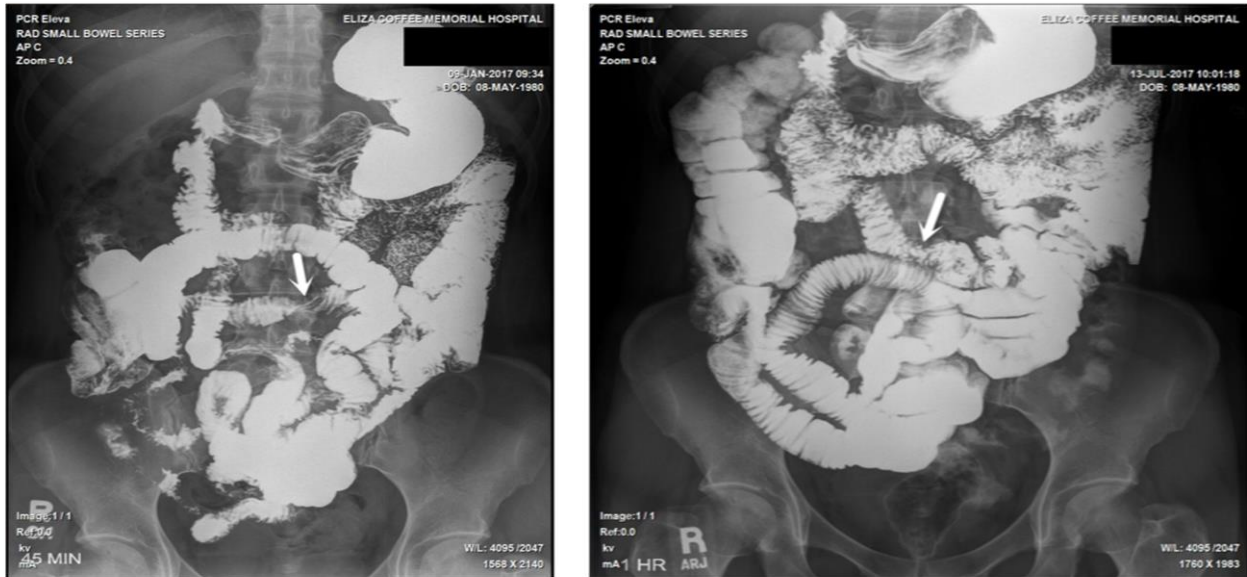
Manual physiotherapy has been previously reported as successful in treating adults with a spectrum of adhesive pathologies spanning orthopedics, radiculopathy, and female infertility.[26-33] Furthermore, the manual physiotherapy regimen utilized in the current study, CPA, has previously been shown effective in disrupting adhesions, decreasing pain, and improving the overall quality of life in patients with recurrent SBO.[34-37] CPA integrates techniques from an array of manual modalities to optimize individualized treatment, focusing intently on the patient's specific areas of restriction. Application of a variety of site-specific pressures across restrictive bands of adhered tissues and structures are employed, progressing from superficial to deep

tissues.[38] Furthermore, peri-visceral and interstitial adhesions are addressable via the CPA technique, while limited organ motility was treated using visceral manipulation.[39] Ultimately, the CPA regimen is designed to facilitate the manual deformation of adhesions for increased mobility of affected tissues and organs. While focused on deforming and detaching fibrous adhesions, the non-invasive nature of this approach does not appear to promote new adhesive formation.

The current case discussion, in combination with the previously established success of site-specific manual physiotherapy in treating a wide array of intra-abdominal adhesive pathologies, warrants further attention. The patient discussed here was scheduled for additional surgery and at risk for entering a perpetual cycle of symptom exacerbation, decreased quality of life, and adhesiolysis. Avoidance of this vicious predisposition in even a subset of patients holds significant value in alleviating a significant burden of comorbidity, cost, and healthcare resources.



**Figure 1.** A. Magnified spot image of the right lower quadrant from a small bowel follow through with paddle compression demonstrates a short segment stricture of the neoterminal ileum [white arrow]; B. Overhead radiograph from a small bowel follow through demonstrates resolution of the neoterminal ileal narrowing [white arrow] after physiotherapy. The time difference between the images A and B is 6 months. Therapy was initiated five months after the initial small bowel radiography.



**Figure 2.** A. Overhead radiograph from a small bowel follow through demonstrates a short segment stricture of the jejunum in the central abdomen [white arrow]; B. Overhead radiograph from a small bowel follow through demonstrates resolution of the jejunal stricture in the central abdomen [white arrow].

**LEARNING POINTS/TAKE HOME MESSAGES**

- Manual physiotherapy has been previously reported as successful in treating adults with a spectrum of adhesive pathologies.
- Adhesive SBO is preferably managed with conservative, non-operative therapy to minimize patient risk and cost.
- Physiotherapy may be a reasonable, non-operative treatment for SBO patients once the acute obstruction has resolved.

**PATIENT'S PERSPECTIVE**

For me, Clear Passage was the last hope of avoiding surgery. The problem with surgery, in my case, is that it would only cause me to need more surgery in the future. Avoiding surgery was my top priority. I knew that if Clear Passage was my last hope, then it was worth trying.

My week of therapy was relaxing for the most part. My therapist was very kind and did a good job explaining everything to me. Upon leaving, I was given instructions on at-home treatment to continue indefinitely. A month after receiving

therapy, I had a follow-up x-ray, which proved that the therapy had in fact fixed my problem. That certainly made it to the list of one of the best days of my life. Eight months later, I continue to do the routine therapy at home. It does not take a lot of time and it is not difficult.

**REFERENCES**

1. Duron JJ. Postoperative intraperitoneal adhesion pathophysiology. *Colorectal Dis.* 2007;9 Suppl 2:14-24.
2. Arung W, Michel M, Olivier D. Pathophysiology and prevention of postoperative peritoneal adhesions. *World J of Gastroenterol.* 2011;17:4545-4553.
3. Beck DE, Ferguson MA, Opelka FG, et al. Effect of previous surgery on abdominal opening time. *Dis Colon Rectum.* 2000;43:1749-1753.
4. Coleman MG, McLain AD, Moran BJ. Impact of previous surgery on time taken for incision and division of adhesions during laparotomy. *Dis Colon Rectum.* 2000;43:1297-1299.
5. Parker MC. Epidemiology of adhesions: the burden. *Hosp Med.* 2004;65:330-336.
6. Tirumani H, Vassa R, Fasih N, et al. Small bowel obstruction in the emergency department: MDCT features of common and uncommon causes. *Clin Imaging.* 2014;38:580-588.

7. Osada H, Watanabe W, Ohno H, et al. Multidetector CT appearance of adhesion-induced small bowel obstructions: matted adhesions versus single adhesive bands. *Jpn J Radiol.* 2012;30:706-712.
8. Mucha P. Small intestinal obstruction. *Surg Clin North Am.* 1987;67:597-620.
9. Ellis H. The clinical significance of adhesions: focus on intestinal obstruction. *Eur J Surg Suppl.* 1997;577:5-9.
10. Miller G, Boman J, Shirier I, et al. Natural history of patients with adhesive small bowel obstruction. *Br J Surg.* 2000;87:1240-1247.
11. Takeuchi K, Yasushi T, Tetsu A, et al. Clinical studies of strangulating small bowel obstruction. *The American Surgeon.* 2004;70:40-44.
12. Catena F, Di Saverio S, Kelly MD, et al. Bologna guidelines for diagnosis and management of adhesive small bowel obstruction (ASBO): 2010 evidence-based guidelines of the World Society of Emergency Surgery. *World J Emerg Surg.* 2011;6:5
13. Diaz JJ, Bokhari F, Mowery NT, et al. Guidelines for management of small bowel obstruction. *J Trauma.* 2008;64:1651-1664.
14. Kendrick ML. Partial small bowel obstruction: clinical issues and recent technical advances. *Abdom Imaging.* 2009;34:329-334.
15. Seror D, Feigin, E, Szold, A, et al. How conservatively can postoperative small bowel obstruction be treated? *Am J Surg.* 1993;165:121-125.
16. Tanaka S, Yamamoto T, Kobuto D, et al. Predictive factors for surgical indication in adhesive small bowel obstruction. *Am J Surg.* 2008;196:23-27.
17. Jeong WK, Lim SB, Choi HS, et al. Conservative management of adhesive small bowel obstructions in patients previously operated on for primary colorectal cancer. *J Gastrointest Surg.* 2008;12:926-932.
18. Cox MR, Gunn IF, Eastman MC, et al. The safety and duration of non-operative treatment for adhesive small bowel obstruction. *Aust N Z J Surg.* 1993;63:367-371.
19. Fevang BT, Jensen D, Svanes K, et al. Early operation or conservative management of patients with small bowel obstruction? *Eur J Surg Suppl.* 2002;168:475-481.
20. Fevang BT, Fevang J, Lie SA, et al. Long-term prognosis after operation for adhesive small bowel obstruction. *Ann Surg.* 2004;240:193-201.
21. HCUPnet: A tool for identifying, tracking, and analyzing national hospital statistics, 2012.
22. Strik C, Stommel MWJ, Schipper LJ, et al. Risk factors for future repeat abdominal surgery. *Langenbeck's Archives of Surgery.* 2016;401:829-837.
23. Peters AA, Trimbos-Kemper GC, Admiraal C. A randomized clinical trial on the benefit of adhesiolysis in patients with intraperitoneal adhesions and chronic pelvic pain. *Br J Obstet Gynaecol.* 1992;99:59-62.
24. Chan CL, Wood C. Pelvic adhesiolysis - the assessment of symptom relief by 100 patients. *Aust N Z J Obstet Gynaecol.* 1985;25:295-298.
25. Steege JF, Stout AL. Resolution of chronic pelvic pain after laparoscopic lysis of adhesions. *Am J Obstet Gynecol.* 1991;165:278-281.
26. Sampson S, Meng M, Schulte A, et al. Management of Dupuytren contracture with ultrasound-guided lidocaine injection and needle aponeurotomy coupled with osteopathic manipulative treatment. *J Am Osteopat Assoc.* 2011;111:113-116.
27. Boyles R, Toy P, Mellon J, et al. Effectiveness of manual physical therapy in the treatment of cervical radiculopathy: a systematic review. *J Man Manip Ther.* 2011;19:135-142.
28. Şenbursa G, Baltacı G, Atay ÖA. The effectiveness of manual therapy in supraspinatus tendinopathy. *Acta Orthop Traumatol.* 2011;45:162-167.
29. Gaspar PD, Willis FB. Adhesive capsulitis and dynamic splinting: a controlled, cohort study. *BMC Musculoskelet Disord.* 2009;10:111.
30. Wurn BF, Wurn LJ, Patterson K, et al. Decreasing dyspareunia and dysmenorrhea in women with endometriosis via a manual physical therapy: Results from two independent studies. *J Endometr.* 2011;3:188-196.
31. Wurn BF, Wurn LJ, King CR, et al. Treating fallopian tube occlusion with a manual pelvic physical therapy. *Altern Ther Heal Med.* 2008;14:18-23.
32. Wurn BF, Wurn LJ, King CR, et al. Treating female infertility and improving IVF pregnancy rates with a manual physical therapy technique. *Med Gen Med.* 2004;6(2):51.
33. Kramp ME. Combined manual therapy techniques for the treatment of women with infertility: a case series. *J Am Osteopath Assoc.* 2012;112:680-684.
34. Rice AD, Reed ED, Patterson K, et al. Clearing bowel obstruction and decreasing pain in a

- terminally ill patient via manual physical therapy. J Palliat Med. 2013;16:222-223.
35. Rice AD, Wakefield LB, Patterson K, et al. Decreasing adhesions and avoiding further surgery in a pediatric patient involved in a severe pedestrian versus motor vehicle accident. *Pediatr Rep.* 2014;6(1):5126.
36. Rice A, King R, Reed E, et al. Manual physical therapy for non-surgical treatment of adhesion-related small bowel obstructions: two case reports. *J Clin Med.* 2013;2:1-12.
37. Rice AD, Patterson K, Reed ED, et al. Treating small bowel obstruction with a manual physical therapy: a prospective efficacy study. *Biomed Res Int.* 2016;1:8.
38. 2011 GoOT. <http://www.aacom.org/resources/bookstore/Documents/GOT2011ed.pdf>

