



International Journal of Animal Research (ISSN:2575-7822)



Biochemical Changes Caused by Eimeria spp in Broiler Chickens

Samrawit Melkamu¹, Mersha Chanie² and Mulat Asrat³

¹School of Veterinary Medicine, Samara University, ETHIOPIA

² Faculty of Veterinary Medicine, University of Gondar, Ethiopia

³School of Veterinary medicine, Wollo University, Ethiopia

ABSTRACT

This experimental study was performed to investigate the effect of coccidia infestation on biochemical parameters in broiler chicken. The experimental animals (n=100) were randomly allocated into four equal groups, group one (G-I), group two (G-II), group three (G-III) and group four (G-IV) with 25 chickens in each group. The G-I, G-II, and G-III were treatments groups challenged by different Eimeria sporulated oocysts, while G-IV served as the control group. In this study, the infective dose of *E. tenella* (G-I), *E. acervulina*(G-II) and mixed Eimeria spp (G-III) was 2x10⁴ sporulated Eimeria oocyst inoculated orally at three weeks of age in broiler chicken and subsequent alterations in different plasma biochemical constituents were evaluated at interval of 5, 7 and 9 day of post inoculation. Serum total protein values after challenge showed statistically significant decrease in group one, group two and group three in comparison with group four. Further, significant decrease total protein value was noticed on 7 day of post infection in group one and group two. The mean values of serum glucose between the infected and control group at 5, 7 and 9 day of post infection which revealed non-statistically significant difference. Coccidiosis due to *E. tenella*, *E. acervulina* and mixed identified Eimeria spp. infection in chicken showed highly statistically significant increase in serum ALT and AST level as compared with control group. This was also significant increase in infected group on 7 day of post infection. But, no significant variation among the infected groups were on 5 and 9 day of post infection.

Keywords: Coccidiosis, *E. tenella*, Oocyst, Poultry

*Correspondence to Author:

Samrawit Melkamu

School of Veterinary Medicine, Samara University, ETHIOPIA

How to cite this article:

Samrawit Melkamu, Mersha Chanie and Mulat Asrat. Biochemical Changes Caused by Eimeria spp in Broiler Chickens. International Journal of Animal Research, 2019; 4:24.

 eSciPub
eSciPub LLC, Houston, TX USA.
Website: <http://escipub.com/>

Introduction

Avian coccidiosis is the major problem in poultry industry worldwide (Jadhav *et al.*, 2011). The disease has major economic impacts on poultry through reduction of performance and productivity. The annual worldwide cost is estimated at about \$800 million. These estimates include the costs of prophylactic in feed medication for broilers and broiler breeders, alternative treatments if medication fails and losses due to mortality, morbidity, impaired growth rate, temporary reduction of egg production in layers and poor feed conversion of chickens that survive outbreaks (Asadi *et al.*, 2015).

Biochemical analysis is the predominant method of disease monitoring in commercial poultry production system (Morris and Gasser, 2006). Serum enzyme activity is primarily used to determine whether pathological process, cellular injury and necrosis is presented and this helps to localize the disease process to a particular cell type. The specific diagnosis of infection plays a key role in the prevention, surveillance and control of coccidiosis (Irizaary-Rovira, 2004). Infection with coccidian parasites in laying hens which have highly significant increase in serum ALT and serum AST level indicates a significant damage of cell lining of the caecal wall along with their inflammation and severe blood loss from the body may be attributed to increased AST activity (Mondal *et al.*, 2011). The specific diagnosis of *Eimeria* infection plays a key role in the prevention and control of coccidiosis. The purpose of this study was to evaluate biochemical changes in broiler chickens experimentally infected with *Eimeria*.

MATERIALS AND METHODS

Study area

The experimental study was conducted in the Faculty of Veterinary Medicine at the premises of Tewodrose Campus, University of Gondar. The area is found in Amhara National Regional State, located in the north-western part of Ethiopia, (12.3° to 13.38° north latitudes and

35.5° to 38.3° east longitudes) (NMA, 2011). The research was conducted from November 2015 to April 2016.

Experimental animals and grouping

One hundred day-old Ross broiler breed chickens were purchased for this experiment from Alema, a private commercial broiler farm, Debre Zeit, Ethiopia. Unsexed day old chickens were randomly and equally allocated into four groups. All groups were maintained at the same management system. The chickens were reared for eight weeks in separate room under strict biosecurity measures and no vaccine was used during the study period. On the start of the experiment the birds were tagged with identification numbers on their wing and leg in each group.

Housing and management of experimental chickens

In this study, day-old chickens were kept with floor housing system. The house, feeder, water utensils were thoroughly cleaned, disinfected prior to stocking of chickens. The utensils were also cleaned daily to avoid reinfection and contamination. Thus, the chickens were reared under strict coccidia free conditions through repeated cleaning and disinfection. Chickens were fed ad libitum on a commercial broiler starter, grower and finisher diet based on their ages throughout the period of the experiment. Continuous heating program with 120 watt bulbs were suspended at head height of the birds. The amount of temperature present in the house was measured and recorded by thermometer and the heat released from brooder was adjusted based on the age of chickens from suspended height. The temperature was maintained at 29-31°C for the first week and was reduced by 1-3°C on weekly basis. Bio-safety of chickens was maintained in study area through fenced farm, protected against wild animals and using footbath. The experimental house had gate and there were special store for feed, disinfectant, personal protective equipment's and closing for the researchers and assistance. The current

experiment was conducted with the approval of university of Gondar ethical review board. The experiment was conducted based on the international guidelines of animal experimentation and handling where they were fed adlibitum. The board approved the protocol to be done. Attached here with is the clearance copy.

Experimental design and inoculation of sporulated oocysts

The experimental design used for this research was completely randomized design. The experimental animals (n=100) were randomly allocated into four equal groups: group one (G-I), group two (G-II), group three (G-III) and group four (G-IV) with 25 chickens in each group. The G-I, G-II, and G-III were treatments groups challenged by different *Eimeria* sporulated oocysts, while G-IV served as the control group. All chickens were maintained until the 10th day of age the experiment with a ration containing anticoccidial additives following the recommended producer. After the 10th days of age, the chickens were fed on a ration without anticoccidial additives until the end of experiment. Adlibitum provision of feed and water were maintained. Faecal material from each group was examined at 10th and 21th days of age before the infection, to ensure that the chickens were free from coccidia or other parasitic diseases. Additionally, blood examination was conducted for the detection of pathogenic bacterial agents. One bird from each group was sacrificed and examined to confirm the absence of any parasitic stage of *Eimeria* species and other pathological lesions at 21th day of age.

The treatment groups of chickens (G-I, G-II, G-III) were infected artificially infected with sporulated *Eimeria* oocysts at the age of three weeks as described by You (2014). They were infected orally with infective dose of 2×10^4 sporulated oocysts of *E.tenella*, *E. acervulina* and field isolated mixed *Eimeria* oocysts. The G-I chickens were infected with *E. tenella*, G-II with *E. acervulina* and G-III with mixed *Eimeria*

spp. (*E. acervulina*, *E. tenella*, *E. necatrix* and *E. maxima*). G-IV was remained as uninfected control groups.

Preparation of infective *Eimeria* species for the experiment

Pure culture *E. tenella*, *E. acervulina* and mixed identified *Eimeria* species were used for this experiment. The pure cultures of *E. tenella* and *E. acervulina* were acquired from India. The mixed *Eimeria* species were identified from the naturally infected chickens. For identification of these mixed species, oocysts were collected from a total of 22 local and koeykoey breed chickens of different sex and ages of clinically coccidiosis suspected chickens were purchased from Gondar town and donated from Kombolcha poultry research and multiplication centre. The chickens were sacrificed in the laboratory at post-mortem room by cervical dislocation using the technique described by Zander (1999). The gastrointestinal tract was grossly examined carefully. Intestinal contents from the respective sections of intestine with lesions were collected. The floatation technique using sodium chloride solution was applied to harvest oocysts (Bowman, 2003).

The harvested *Eimeria* oocysts were identified by a combination of oocyst size, location in the gut and appearance of the lesions (McDougald and Fitz-Coy, 2008). The different species of *Eimeria* were identified according to the length, width and shape index of the individual oocyst after measuring 50 oocysts in each positive sample using a calibrated ocular microscope (McDougald, 2003).

The identified *Eimeria* spp oocysts were spread out in shallow Petri dish containing 2.5% potassium dichromate ($K_2Cr_2O_7$) solution and incubated with a temperature 29°C, with adequate oxygen and humidity to allowed sporulation. The sporulation of the oocyst was confirmed by taking a drop of the mixture starting from the second day of incubation and examined for the presence of sporocysts under the microscope. The sporulated oocysts were collected and preserved in 2.5% $K_2Cr_2O_7$ and

stored at 4°C. The sporulated oocysts were counted using the McMaster method (Holdsworth *et al.*, 2004).

Biochemical profiles

Two ml of blood was withdrawn from the brachial vein on the 5, 7 and 9 DPI. The collected blood was immediately transferred in to test tube without anticoagulant and allowed to clot at room temperature. After clotting, serum was separated by centrifugation at 3,000 rpm for 5 minutes. The separated serum was collected and stored at -20°C (Meskeremet *al.*, 2013).

Serum total protein

The total protein (TP) level in g /dL was analysed by Modified Biuret, End Point Assay using commercial clinical kit (total protein test kit). The result was expressed as serum total protein g/dL.

Alanine amino transferase

The serum alanine amino transferase (ALT) level was analysed by Modified International Federation of Clinical Chemistry method. A serum alanine amino transferase activity was determined according to recommendations of scientific committee for the International Federation of Clinical Chemistry using commercial kit (Kone Instruments Corp.). The result was expressed as ALT (IU/L).

Aspartate amino transferase

The serum aspartate amino transferase (AST) level was analysed by Modified International Federation of Clinical Chemistry method. Serum aspartate aminotransferase activities were determined according to recommendations of scientific committee for the International Federation of Clinical Chemistry by using a commercial kit (Kone Instruments Corp.). The result was expressed as AST (IU/L).

Serum glucose

The Serum glucose level was analysed by GOD-PAP using commercial clinical kit (glucose reagent set, India). The difference in

absorbance at fixed times during conversion was proportional to the concentration of glucose in the sample. The result was expressed as mg/ dL.

Statistical analysis

The data obtained were stored in Microsoft excel-2007 and analysed by using STATA version 12. The mean and standard deviation were calculated to describe the biochemical parameters recorded during study period. Linear regression analysis was used for the comparisons of biochemical parameters in different periods of 5, 7 and 9DPI in all infected groups were compared with control group. Those differences with $P < 0.05$ were considered statistically significance and those differences with $P < 0.01$ were considered as highly statistical significance.

RESULTS

Biochemical parameter

Serum total protein: The serum total protein (TP) in g/dL level on 5, 7 and 9 DPI in G-I, G-II and G-III infected groups and G-IV were analysed. The TP values after challenge showed statistically significant ($P < 0.05$) decrease in G-I, G-II and G-III in comparison with G-IV. Further significant decrease ($P < 0.05$) TP value was noticed on 7 DPI in G-1, and G-II.

The mean serum total glucose in mg/dL level in G-I, G-II, G-III and G-IV on 5, 7 and 9 DPI were analysed. The mean values of serum glucose between the infected and control group with different DPI which revealed non-statistically significant difference ($P > 0.05$); however non-significant reduction was observed among the groups. The level of glucose in different day of post infection was observed a non-significant differences ($p > 0.05$) among days of post infection.

Aspartate amino transferase

In the current study, a statistically significant rise in serum AST activity in G-I, G- and G-III were recorded when compared to G-IV, but in group one and two significantly increased

($p < 0.05$) on 7 DPI, in group three no statistical difference within days after infection.

Alanine amino transferase

In the present study, coccidiosis due to *E. tenella*, *E. acervulina* and mixed identified *Eimeria* spp. infection in chicken showed highly

statistically significant ($P < 0.01$) increase in serum ALT level as compared with control group. This was also significant ($P < 0.05$) increase in infected group on 7 DPI. But no significant ($P > 0.05$) variation among the infected groups was on 5 and 9 DPI.

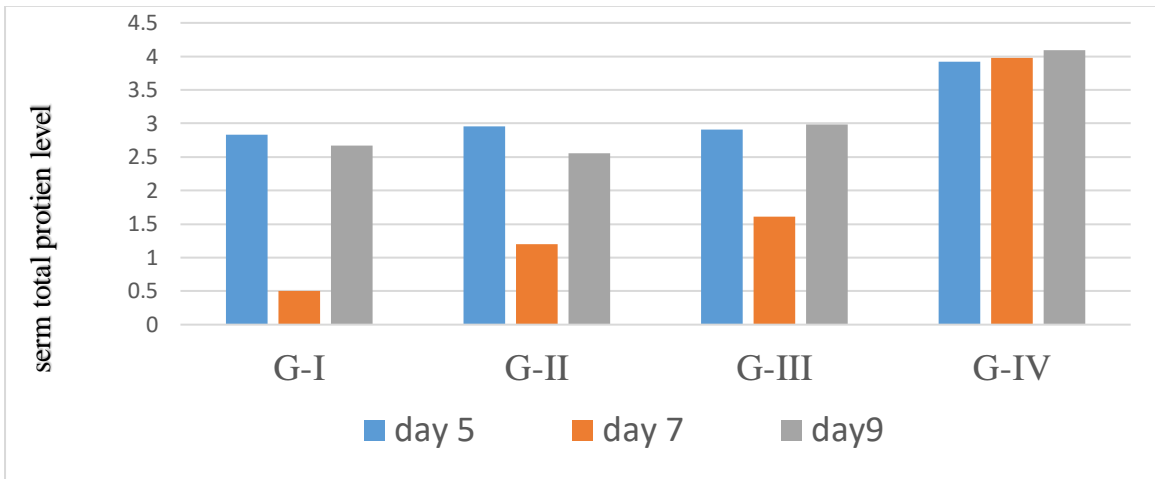


Figure 1. The mean values of serum total protein in four groups on three different day of post infection Serum glucoses

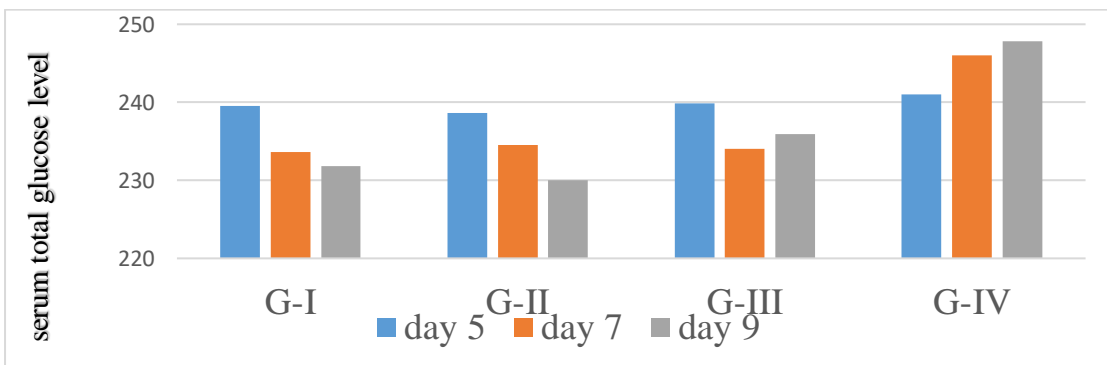


Figure 2. The mean serum total glucose value in four groups in different day of post infection

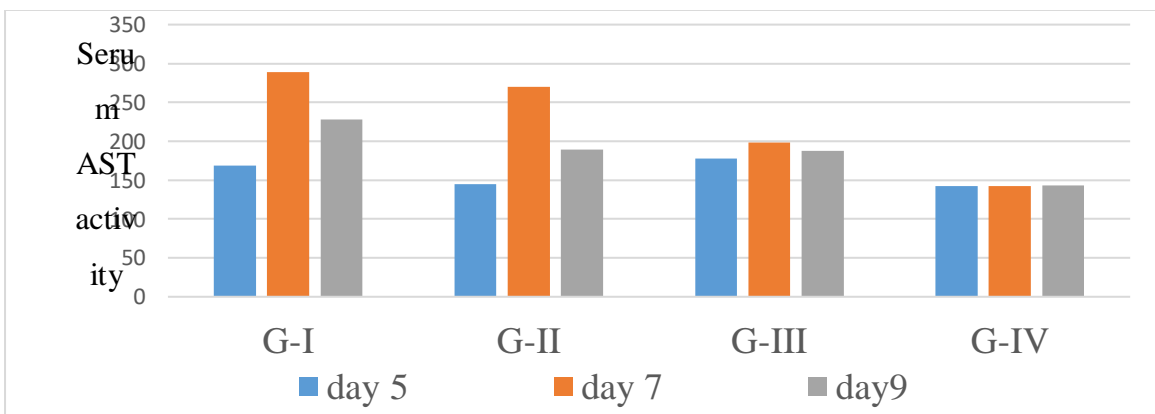


Figure 3. The mean variance of serum Aspartate amino transferase activity within four groups in different day of post infection

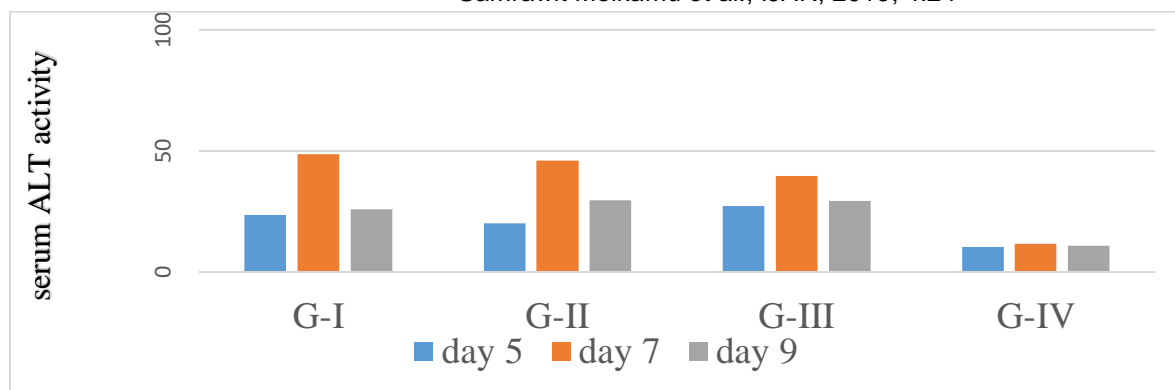


Figure 4. The mean value of serum alanine amino transferase activity within four groups in different day of post infection

DISCUSSION

The marked decrease in TP was observed in infected groups compared to control group. The values are found to be decreased with in infected groups in different day of 7 and 9 PI. The present finding was in accordance with Fagner (2014) who reported significant reduction in total serum protein different *Eimeria* spp. infected chickens on different DPI. In the present study, TP reduction was observed might be due to nutrient mal absorption, liver changes and formation of inflammatory exudate rich in blood proteins, acute stress that leads to cortisol secretion and catabolism of protein (Kerr, 2002). Also acute haemorrhage causes large loss of plasma protein followed by rapid movement of interstitial fluid without protein into the plasma compartment to induce acute hypo-proteinemia.

A highly significant ($P < 0.01$) increase in serum AST activity in infected group was observed compared to control group on different DPI. However, no significant ($P > 0.05$) variation was observed with in infected groups on different days 5, 7 and 9 DPI. This finding is supported by Mondal *et al.* (2011) who demonstrated that AST activity showed highly significant increase in infected chickens with *E. tenella*. However, the present study contradicts with earlier reports of Meskerem *et al.* (2013) who reported AST activity decrease in *E. tenella* and *E. brunetti* innaturally infected broilers chickens.

The increased serum AST could be due to severe damage of cell lining of the caecal wall along with their inflammation and severe blood loss causing tissue loss from the body, cellular membrane degeneration, diffused tissue degeneration and loss may be attributed to increased AST activity.

Infection with *Eimeria* in chicken showed highly significant increase in serum ALT level as compared with control group, and also significant variation with in infected group on 7 DPI. The present study are similar with earlier studies by Abd El-Maksoud *et al.* (2014) who reported that liver function test of the infected chicken with *Eimeria* spp. showed a significant increase in the serum ALT activity. On contrary, the present result in disagreement with Meskerem *et al.* (2013) who reported that highly significant reduction in serum ALT activity in a field isolate of *E. tenella* infected chickens was noted compared to control group. But, no significant variation in infected group on 5, 7 and 9 DPI. In the present study elevated ALT levels might be due to hepato cellular and sever intestinal tissue damage. Serum level of transaminases is affected by reduced feed intake which birds lost appetite during the peak of infection this might have affected the transaminase level.

The reduction of serum glucose values were recorded in experimentally *E. tenella*, *E. acervulina* and mixed *Eimeria* spp. infected groups on 5, 7 and 9 DPI in comparison with

control group. Similar finding have been reported by Abd El-Maksoud *et al.* (2014) who suggested that in birds suffered from coccidia infection serum glucose level was decreased. Also Hirani *et al.* (2007) who suggested that serum glucose level of *E.necatrix* infected birds showed no significant difference compared with control group. On the contrary, Mondal *et al.* (2011) reported that serum glucose values were significantly increased with infection by field isolate of *E. tenella* in broiler chicken. The decrease in serum glucose might be due to anorexia and intestinal tract inflammation which inhibit glucose absorption, using up liver glycogen reserves and in severe infections hypoglycemia is due to inhibition of liver glycogenolysis.

REFERENCES

1. Abd EL-Maksoud, H.A., Afaf, D., Abdel-Magid, M. and EL-Badry, M.A. (2014): Biochemical effect of coccidia infestation in laying hen. *Benha veterinary medical journal*, 26(1):127-133.
2. Asadi, I. H., Asadi, I. M., Youssefi, M.R. and Abouhosseini, T. M. (2015): Growth performance parameters in chicken experimental coccidiosis treated with Diclazuril and Clopidol: The need for assessing new anticoccidial resources. *Iranian Journal of Veterinary Medicine*, 9(3):189-194.
3. Bowman, D. (2003): Parasitology for veterinarians. 8thed. U.S.A.: Saunders. Broiler chicks *Gallus domesticus* in Riyadh city, Saudi Arabia. *Journal of King Saud*, 9(1):12-19.
4. Fagner L. C. F. (2014): Metabolic alterations in broiler chickens experimentally infected with sporulated oocysts of *Eimeria maxima*. *Braz. Journal of veterinary parasitology*, 23(3): 309-31
5. Hirani, N.D., Hasnani, J.J., Dhami, A.J. and Khanna, K.A. (2007): Haematobiochemical profiles of broilers affected with coccidiosis. *Journal of veterinary parasitology*, 21: 25- 28.
6. Holdsworth, P.A., Conway, D.P., McKenzie, M.E., Dayton, A.D., Chapman, H.D., Mathis, G.F., Skinner, J.T., Mundt, H.C. and Williams, R.B. (2004): World association for advancement of veterinary parasitology guidelines for evaluating the efficacy of anticoccidial drugs in chickens and turkeys. *Veterinary Parasitology*, 121:189-212.
7. Irizaary-Rovira, A.R. (2004): Avian and reptilian clinical pathology (Avian haematology and biochemical analysis), Section XI, In R.L. Cowell, (ed.). *Veterinary clinical pathology secrets*. Elsevier Inc. St. Louis, MO, USA., Pp.282-313.
8. Jadhav, B.N., Nikam, S.V., Bhamre, S.N. and Jaid, E.L. (2011): Study of *E.necatrix* in broiler chicken from Aurangabad District of Maharashtra state India. *Journal of International Research*, 1(11):11-12
9. Kerr, M.G. (2002): Clinical biochemistry and haematology. In: *Veterinary laboratory medicine*. Oxford, UK: Blackwell Scientific Publications, Pp 1-30.
10. McDougald, L.R. (2003): Coccidiosis. In: Saif, M. (ed). *Diseases of poultry*. Iowa State Press, Blackwell Publishing Company, USA, 11th ed. Pp.974-991.
11. McDougald, L.R. and Fitz-Coy, S.H. (2008): Protozoal infection, In: Saif, Y.M. (ed.). *Disease of poultry*. 12th ed. Blackwell Publishing. Ames, IA, USA. Pp.1068-1080.
12. Meskerem, A., Chaiwat, B., Nirat, G. and Montakan, V. (2013): Haematological, biochemical and histopathological changes caused by coccidiosis in chickens. *Kasetsart Journal (Nat. Sci.)*, 47:238-246
13. Mondal, D.K., Saibal, C., Subhasish, B., Asit, K. and Debasis, B. (2011): Serum biochemical indices at various stages of infection with a field isolate of *E. tenella* in broiler chicken, *Veterinary World*, 4:9.
14. Morris, G.M. and Gasser, R.B. (2006): Biotechnological advances in the diagnosis of avian coccidiosis and the analysis of genetic variation in *Eimeria*. *Advance biotechnology*, 24:590-603.
15. NMA (2011): Annual climatically bulletin for the year 2011. National Metrological Agency of Ethiopia.
16. Patra, G., Rajkhowa, T.K., Ali, M.A., Tiwary, J.G. and Sailo, L. (2009): Studies on clinical, gross, histopathological and biochemical parameters in broiler birds suffered from *E. necatrix* infection in Aizawl District of Mizoram. *India International Journal of Poultry Science*, 8(11):1104-1106.
17. You, M.J. (2014): The comparative analysis of infection pattern and oocyst output in young broiler chicken, *E.tenella*, *E.maxima* and *E. acervulina*. *Veterinary World*, 7(7):542-547.
18. Zander, D.V. (1999): Principles of disease prevention, diagnosis and Control. In: Hofstad, M.S., Calnek, B. W., Helmboldt, C. F., Reid, W. M. and Yoder, J.H. (ed.). *Diseases of poultry*, 7th ed. USA, Iowa State University Press/Ames, Iowa, Pp.3-48.