



International Journal of Case Reports (ISSN:2572-8776)



Ansa Pancreatica: An Uncommon Cause Accounting for Recurrent Pancreatitis in Children

Syeda Namayah Fatima Hussain¹, Munir Iqbal Malik², Sabeen Abid Khan³

¹A-11, Rabbia Garden, Garden East, Britto Road, Karachi.

²Department of Paediatrics, Shifa International Hospital, Pitras Bukhari Road, Islamabad.

³House 150, Street 11, E-11/4, Islamabad

ABSTRACT

Acute recurrent pancreatitis is a rare entity in children. It can be caused by a number of reasons, anatomical variations being one of them. Pancreatica divisum is the most common form of ductal anomaly while ansa pancreatica is the least studied and explored. In recurrent pancreatitis, Ansa Pancreatica was recently found to be a key risk factor. It is usually found among adult alcoholics. We submit a report of a rare but important cause of acute recurrent pancreatitis; an 11-year-old child with 2 previous episodes of pancreatitis diagnosed with ansa pancreatica on magnetic resonance cholangiopancreatography (MRCP). He was advised to get stenting of Pancreatic duct. To the best of our belief, only another case has been reported in the pediatric population.

Keywords: Acute recurrent pancreatitis, ansa pancreatica, pancreatica divisum

*Correspondence to Author:

Syeda Namayah Fatima Hussain
A-11, Rabbia Garden, Garden East,
Britto Road, Karachi.

How to cite this article:

Syeda Namayah Fatima Hussain,
Munir Iqbal Malik, Sabeen Abid
Khan. Ansa Pancreatica: An Un-
common Cause Accounting for
Recurrent Pancreatitis in Children
. International Journal of Case Re-
ports, 2019 4:60

 eSciPub
eSciPub LLC, Houston, TX USA.
Website: <http://escipub.com/>

Introduction

Acute recurrent pancreatitis in childhood and adolescence is a rare occurrence and poorly understood. Few single-center studies have approximated 9-35% of children with acute pancreatitis undergo recurrent episodes [1-3]. The etiology in children differ from adults and consist of genetic mutations, trauma, infection, drugs, anatomic malformations and metabolic disorders. Acute pancreatitis has a number of anatomical causes, of which pancreatic divisum is the most common [4]. Most anomalies and variants of pancreas are found incidentally and have no clinical significance. However, a few play a role in causing pancreatitis.

Ansa pancreatica, a rare ductal anomaly, bridges the main pancreatic and accessory pancreatic duct. In this pancreatic duct variant, a branch descends as an extension of the main pancreatic duct; later ascending to form a loop which terminates at the minor papilla. It is associated with recurrent acute pancreatitis due to causing hindrance in the drainage of pancreatic juice [5]. Reports have shown that patients with ansa pancreatica, especially alcoholics, are likely to develop pancreatitis [4,6]. During the literature review, despite there being a couple of case reports on ansa pancreatica in adults, there was only one reported in children [7].

We submit a report of acute recurrent pancreatitis in an 11-year-old male, who on magnetic resonance cholangiopancreatography (MRCP) was discovered to have ansa pancreatica. The purpose of this case is to identify ansa pancreatica as a cause of recurrent pancreatitis in children.

Informed consent from the patient and approval of the IRB committee was obtained for this study.

Case Report

An 11-year-old male child presented with severe epigastric pain, radiating to the back since one day. Concomitantly, he developed vomiting and nausea but no fever. He had two similar episodes in June and August 2018 and following investigations had been diagnosed as acute recurrent pancreatitis. His family history for pancreatitis or any other disease was insignificant.

On admission, his abdomen was found to be non-tender and soft on examination without any visceromegaly. Normoactive bowel sounds were present on auscultation. Neither edema nor palpable lymphadenopathy was present. General examination was unremarkable.

Patient was given supportive care and detailed laboratory workup was started. His total leukocyte count along with hemoglobin and liver function tests were normal. At admission, his serum amylase level was 523 International Unit per liter (IU/L) (Reference range 0-160 IU/L) and serum lipase was 1972 IU/L (Reference range: 1-130 IU/L.) Serum calcium, sodium alongside triglycerides were within normal bounds. Patient underwent an extended autoimmune profile which came negative. An ultrasound of the abdomen revealed mild left renal pelvicalyceal fullness but it did not reveal any gallbladder stone or sludge. The patient was hospitalized and kept nil per os (NPO) while being managed with intravenous fluids and antibiotics.

His MRCP was performed which revealed a bulky pancreas with mild peripancreatic stranding consistent with findings of pancreatitis. It also showed mild intra and extrahepatic biliary dilation with narrowing of a small segment in distal common hepatic duct. Variable pancreatic ductal anatomy was noted showing the ventral duct (Wirsung duct) with no communication with the dorsal duct while draining into the minor papilla. The pancreaticogram

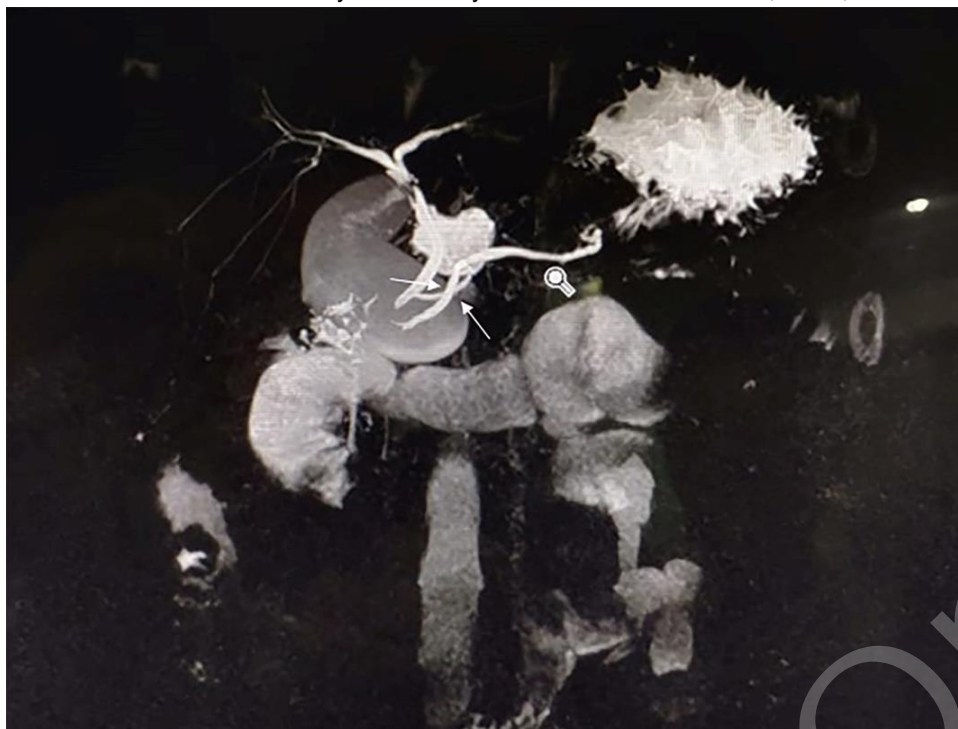

Figure 1 - Magnetic resonance imaging exhibiting Ansa Pancreatica. Magnetic resonance cholangiopancreatography displays a looping duct in the pancreatic head (white arrows) opposed to a conventional accessory duct. On this image, the additional duct can be spotted crossing the main pancreatic duct.

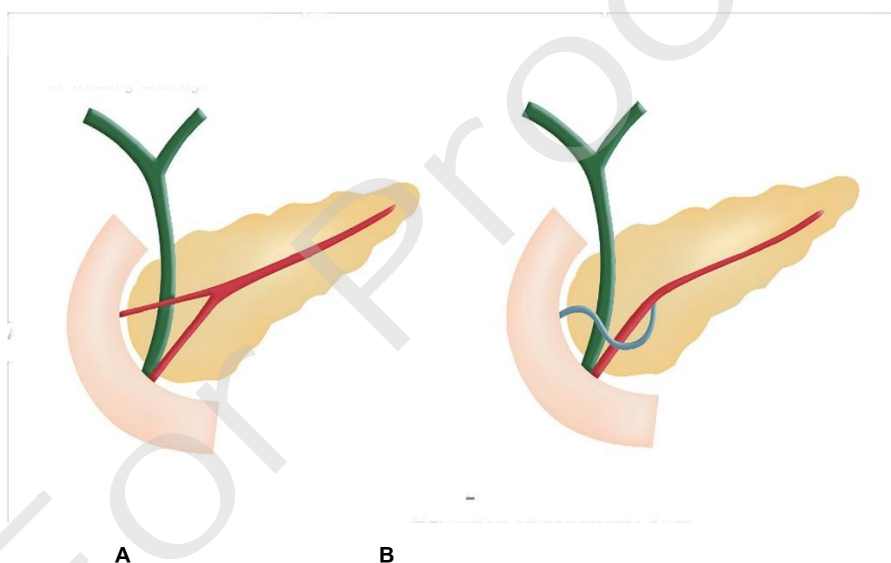


Figure 2 – Diagram of normal pancreatic ducts (A) and ansa pancreatica (B). Type (A) represents a normal pancreas where both common bile duct and main pancreatic duct (Duct of Wirsung) meet accompanied by its accessory duct which runs horizontally and drains in or adjoining the minor papilla. In type (B) Duct of Santorini courses towards the Duct of Wirsung forming a sigmoid curve running caudally first and then rightward.

Type (A) represents a normal pancreas where the Duct of Wirsung (main pancreatic duct) joins the common bile duct while joining the Duct of Santorini (accessory duct) which drains horizontally approaching the minor papilla. In type (B), the Duct of Santorini (accessory duct) courses towards the Duct of Wirsung (main pancreatic duct) forming a sigmoid curve running caudally first and then rightward.

revealed an arch ending adjacent to the minor papilla formed by a branch emerging from the main pancreatic duct [Fig 1]. This curved variant matches with the description of ansa pancreatica [Fig 2].

Following the antibiotics, the abdominal pain subsided and the patient's condition improved in the next 5 days. Repeat serum lipase showed a considerable decrease to 1195 IU/L. He was discharged on low fat diet and regular follow-ups. Hepatobiliary consultation was given to the family with stenting and sphincterectomy recommended.

Discussion

Despite acute pancreatitis occurring more frequently in adults, there has been a recent rising trend in children [8]. It carries a significant mortality and morbidity risk in children with increased economic burden requiring a mean stay of 13.2 days in the hospital and 28% of patients needing total parenteral nutrition [8]. The known associations in children are genetic mutations, trauma, structural abnormalities, drug, viral infections while 23% are classified as idiopathic [7].

According to a study in Japan, amongst adult patients with acute pancreatitis, 2.9% had pancreatica divisum, 0.85% had ansa pancreatica while a winding main pancreatic duct was found in 6.3%. The risk of pancreatitis both acute and recurrent came out to be considerably higher in patients suffering from ansa pancreatica (20%) in contrast to the ones without it (0.52%) [5].

Pancreatica divisum is the most frequent structural abnormality responsible for 5-8% of cases [4,9]. One of the rarest cause is ansa pancreatica, where an arched duct replaces the normal accessory duct in the pancreatic head between dorsal and ventral ducts. This accessory pancreatic duct, with a reverse S- shape, branches from the

main pancreatic duct, running into the caudal side of the ventral, terminating within or adjoining the minor papilla [4,6].

MRCP and Endoscopic retrograde cholangiopancreatography (ERCP) are considered to be the preferred diagnostic tests to identify the anatomical variant when it becomes symptomatic. In ERCP, the sigmoid branch of ansa pancreatica may be wrongly identified as annular pancreas. However, differentiation can be done on the basis of a pancreatogram. In annular pancreas, the looping branch when approaching the minor papilla can be seen crossing the duodenum whereas in ansa pancreatica the branch does not cross the duodenum.

There is poor drainage of pancreatic juice in ansa pancreatica since the main pancreatic duct and side branch meet at a sloping angle, making patients vulnerable to pancreatitis especially in alcoholism and functional stenosis of sphincter of Oddi [6]. This makes it a disease of the elderly.

However, the child in this case with relapsing episodes of acute pancreatitis proved ansa pancreatica to be a rare but possible differential diagnosis in the pediatric age group. Despite having sufficient data on other ductal and anatomical variations, ansa pancreatica has been largely ignored. Considering the paucity of data and lack of statistics, the need to follow outcomes and data becomes necessary for etiological assessment of recurrent pancreatitis and to give children a better quality of life.

Conclusion

Ansa Pancreatica could be a possibility in children with episodes of recurrent non-biliary acute pancreatitis despite being very rare. More studies need to be done which focus on the causes and incidence of this ductal variation in the age group below 18.

Conflict of Interest

We have no conflict of interests to declare.

Acknowledgement

We'd like to acknowledge Shifa International Hospital's Department of Radiology for providing us with the images and findings.

References

1. Park A, Latif SU, Shah AU: Changing referral trends of acute pancreatitis in children: A 12-year single-center analysis. *J Pediatr Gastroenterol Nutr.* 2009, 49:316-322. 10.1097/MPG.0b013e31818d7db3.
2. Sanchez-Ramirez CA, Larrosa-Haro A, Flores-Martinez S, Sanchez-Corona J, Villa-Gomez A, Macias-Rosales R. : Acute and recurrent pancreatitis in children: etiological factors. *Acta Paediatr.* 2007, 96:534-537. 10.1111/j.1651-2227.2007.00225.x
3. Minen F, De Cunto A, Martelossi S, Ventura A.: Acute and recurrent pancreatitis in children: exploring etiological factors. *Scand J Gastroenterol.* 2012, 47:1501-150. 10.3109/00365521.2012.729084
4. Lehman GA: From congenital anomalies of the pancreas. In *Gastroenterologic Endoscopy.* Sivak Jr MV. (ed): Saunders Company, Philadelphia, P.A.; 2000. 2:1084-97.
5. Yamakawa Hayashi, Takana & Gonoj, Wataru & Yoshikawa, Takeharu & Hayashi, Naoto & Ohtomo, Kuni.: Ansa pancreatica as a predisposing factor for recurrent acute pancreatitis. *World Journal of Gastroenterology.* 2016, 22:8940-48. 10.3748/wjg.v22.i40.8940
6. Tanaka T, Ichiba Y, Miura Y, Itoh H, Dohi K. : Variations of the pancreatic ducts as a cause of chronic alcoholic pancreatitis; ansa pancreatica.. *Am J Gastroenterol.* 1992, 87:806.
7. Kim HM, Park JY, Kim MJ. : Ansa Pancreatica: A Case Report of a Type of Ductal Variation in a Patient with Idiopathic Acute Recurrent Pancreatitis. *J Korean Soc Radiol.* 2010, 63:83-86. 10.3348/jksr.2010.63.1.83
8. Benifla M, Weizman Z.: Acute Pancreatitis in Childhood: Analysis of Literature Data. *J Clin Gastroenterol.* 2003, 37:169-172
9. Cotton PB.: Congenital anomaly of pancreas divisum as cause of obstructive pain and pancreatitis. *Gut.* 1980, 21:105-114. 10.1136/gut.21.2.105

