



## International Journal of Case Reports (ISSN:2572-8776)



# Recurrence of Graves' disease in thyroid remnant after total thyroidectomy

Óscar Moreno Domínguez<sup>1</sup>, Beatriz Barquiel Alcalá<sup>1</sup>, Alejandro Castro Calvo<sup>2</sup>, Lucrecia Herranz de la Morena<sup>1</sup>

<sup>1</sup>Department of Endocrinology and Nutrition, La Paz Hospital, Madrid, Spain.

<sup>2</sup>Department of Otorhinolaryngology, La Paz Hospital, Madrid, Spain

### ABSTRACT

Recurrences of Graves' disease (GD) after total thyroidectomy (TT) are uncommon, with few cases reported in literature. This article describes the case of a 58-year-old man who was treated with TT due to GD over 15 years ago. A progressive reduction of levothyroxine treatment was observed due to persistent sub-clinical hyperthyroidism. Thyroid-stimulating hormone receptor antibodies were detected in blood analysis and in the imaging test, a lesion was identified in the upper left anterolateral cervical region. A histopathological study of the lesion revealed colloid goiter. The patient was diagnosed with GD recurrence in a thyroid remnant and was remitted to an otorhinolaryngologist to remove the lesion. The histopathological study showed diffuse thyroid hyperplasia. The objective of this clinical case report is to highlight this unusual recurrence to better treat and improve long-term outcomes in patients treated with TT.

**Keywords:** Graves' disease, recurrence, thyroid remnant, total thyroidectomy

### \*Correspondence to Author:

Óscar Moreno Domínguez  
Department of Endocrinology and  
Nutrition, La Paz Hospital, Madrid,  
Spain.

### How to cite this article:

Óscar Moreno Domínguez, Beatriz Barquiel Alcalá, Alejandro Castro Calvo, Lucrecia Herranz de la Morena. Recurrence of Graves' disease in thyroid remnant after total thyroidectomy. International Journal of Case Reports, 2020 4:135

 eSciPub  
eSciPub LLC, Houston, TX USA.  
Website: <http://escipub.com/>

**Introduction:**

Graves' disease (GD) is one of the main causes of endogenous hyperthyroidism produced by thyroid-stimulating hormone (TSH) receptor antibodies that stimulate the thyroid gland, increasing its size and the synthesis of thyroid hormones. In addition to symptomatic treatment, an individualized therapy aimed at restoring thyroid function is required (antithyroid agents, radioiodine or surgery)<sup>1</sup>. In regards to the surgery, although there was a debate between performing total thyroidectomy (TT) (complete removal of all visible thyroid tissue) or subtotal thyroidectomy (ST) (deliberately maintaining a part of the thyroid)<sup>2</sup>, currently most authors are positioned in favor of the TT<sup>1, 3, 4</sup>. When analyzing the possible factors involved in the relapse of GD after surgery, only the existence of a thyroid remnant with a weight more than 2g has shown an association with the relapse<sup>5</sup>. This is why TT is currently preferred when reducing the recurrence rate without increasing the adverse effects.

**Case report:**

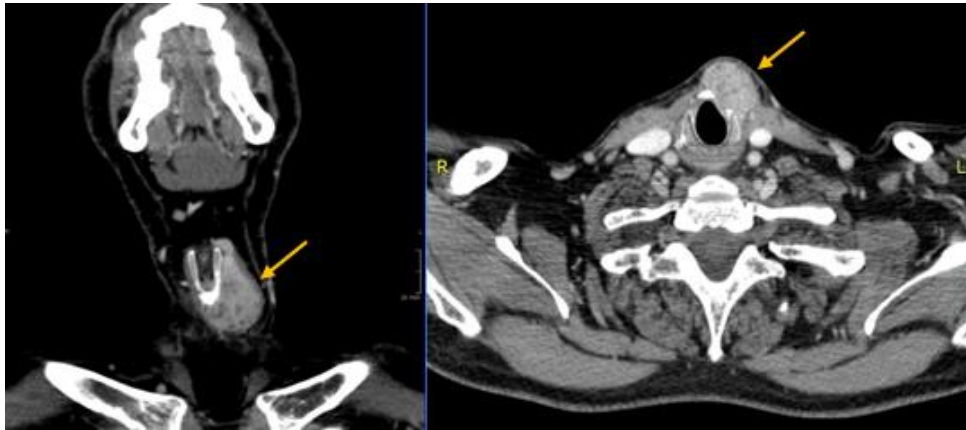
A 58-year-old male who had been previously treated with TT was referred to endocrinology assessment for persistent subclinical hyperthyroidism during the previous 36 months. The patient had a history of smoking (18 cigarettes / day), hypertension treated with enalapril 20 mg/hydrochlorothiazide 12.5 mg one tablet / 24h and amlodipine 5 mg / 24h, hypercholesterolemia treated with simvastatin 10 mg / 24h, discoid lupus treated with hydroxychloroquine 200 mg / 24h and Leiden factor V mutation. The patient had been diagnosed 17 years earlier with GD and was initially treated with antithyroid drugs for 24 months. The patient was subsequently treated with TT without associated complications due to poor control of the disease. The histopathological study revealed diffuse hyperplasia of the thyroid gland. Treatment was started with levothyroxine 125 mcg / 24h and, after stabilization of thyroid function, the patient continued with follow-ups with his primary care

physician. Seventeen years after the surgery, the patient's persistent subclinical hyperthyroidism had forced the dose of levothyroxine to be reduced to 25 mcg / 24h for 6 months, with TSH 0.6 mcUI / mL (0.55- 4.78) at the time of referral. In the anamnesis, the patient denied symptoms of thyrotoxicosis, highlighting only dryness and eye pain. On physical examination: weight 84.5 kg, height 1.77 m, BMI 26.97 kg / m<sup>2</sup>, no palpable lesions at the level of the thyroid bed, highlighting a solid paralaryngeal nodule in the left lateral cervical region that moved when swallowing, conjunctival erythema and mild exophthalmos. Levothyroxine treatment was discontinued and additional tests were requested. Blood analysis revealed: TSH 7.93  $\mu$ UI / mL, free thyroxine (FT4) 0.85 ng / dL (0.78-1.53), total triiodothyronine (T3) 1.04 ng / mL (0.60-1.81), thyroglobulin 123 ng / mL (1.6-59.9), thyroglobulin antibodies <15 IU / mL (<60), thyroid peroxidase antibodies <28 IU / mL (<60), TSH receptor antibodies (TSHrAb) 32.5 IU / L (0.0-2.0). A cervical ultrasound was requested that showed signs of TT and, in the upper left anterolateral cervical region, a solid, well defined, 29 mm oval, solid vascular lesion. A fine needle aspiration was performed with a histopathological study compatible with colloid goiter on probable remnants of thyroid tissue. With these results, GD recurrence ascribable to a probable thyroid remnant was diagnosed. Levothyroxine 25 mcg / 24h was reintroduced and surgical excision was proposed.

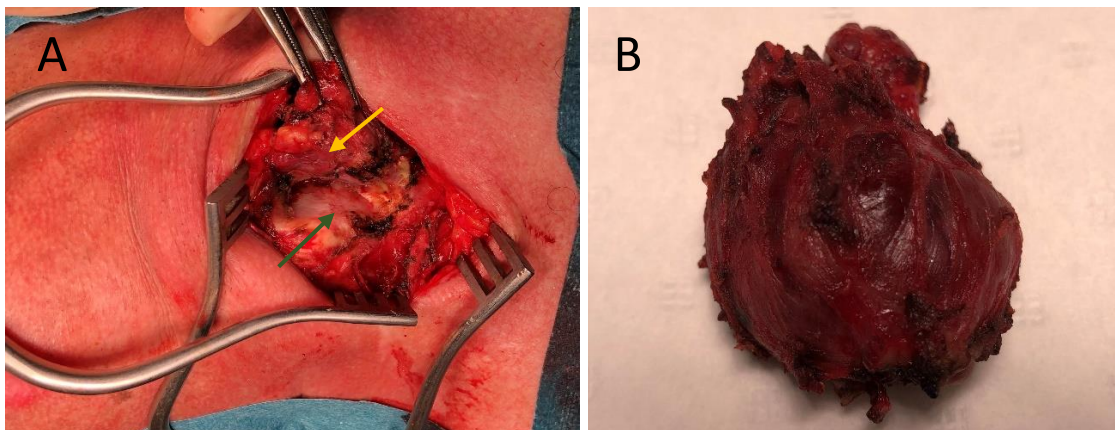
Before the surgery, a cervical computerized tomography (CT) was requested, which showed a hypercaptant and heterogeneous image of nodular morphology in its most caudal portion, where it measured 30x19x28 mm (oblique anteroposterior, transverse and cranio-caudal planes), extending in its cranial portion to the upper portion of the thyroid cartilage through a 6x8 mm band of tissue in relation to thyroid remains (Figure 1). Finally, the excision of the thyroid remnant was performed by the Otorhinolaryngology department, corresponding

to remnant of Labouette's pyramid, which went without complications (Figure 2). The histopathological study showed diffuse thyroid hyperplasia with focal areas of hyperfunction. After 24 months, the patient continues to

maintain a normal thyroid function with levothyroxine 125 mcg / 24h, with TSH 2.06  $\mu$ UI / mL, FT4 1.56 ng / dL, T3 0.99 ng / mL and progressive decrease in TSHrAb, although detectable, of up to 3.1 IU / L.



**Figure 1.** Coronal and transverse sections of cervical CT showing thyroid remnant in relation to the left wing of the thyroid cartilage (yellow arrow).



**Figure 2.** A. Surgical image of the excision of the thyroid remnant (yellow arrow), which is being dissected from the left wing of the thyroid cartilage (green arrow) (the right of the image corresponds to the upper part of the patient). B. Surgical piece of thyroid remnant.

### Discussion:

There are few described cases of GD recurrence after TT, given the associated low relapse rates <sup>1, 6, 7</sup>, this patient being one of the few reported. The published cases refer to relapses in ectopic thyroid tissue <sup>5, 8, 9</sup>, which were resolved surgically.

However, it is important to differentiate ectopic thyroid tissue from thyroid remnants after TT, which is complex in clinical practice. Thus, the existence of post-surgical remnants of the

thyroid parenchyma <1cm is frequent, which is defined as almost total thyroidectomy (ATT). These remnants are most often located at the apex of the upper poles of the thyroid lobes, in the pyramidal lobe or in the area of the Berry ligament. In a study of 102 patients treated with TT, thyroid remnants were found in 33.3%, of which 35.3% had a maximum diameter <1cm (ATT). Regarding the total number of cases with remnants, 70.6% presented them unilaterally with the presence of left remnants being more

common (62.5%). These data are consistent with the location of the remnants observed in our patient. The study authors conclude that it would be advisable to perform a cervical ultrasound 6 months after thyroidectomy, not only in malignant pathology, to be able to reclassify the surgery in: TT (absence of macroscopic remnant), ATT (thyroid remnant <1cm) or ST (remnant thyroid > 1cm) <sup>10</sup>. A postoperative ultrasound in this case would have helped to monitor our patient and estimate the risk of recurrence.

On the other hand, a study carried out in 3044 patients treated with TT due to benign pathology showed 11 cases of recurrence: 1 in the thyroid bed, 4 in the pyramidal lobe, 5 in the thyrotimic tract and 1 in the submandibular region. The recurrence in our patient would correspond to the second most frequently described area, the pyramid of Lalouette or pyramidal lobe, an embryological remnant of the thyroglossal duct that must be properly identified and removed to perform a successful TT <sup>2</sup>.

Our case can be used to improve the postoperative management of patients with GD, in which thyroid remnants after TT can become hyperfunctional tissue in the presence of TSHrAb and hypertrophy over time. This case demonstrates the need to conduct a TT in the GD, taking great care not to leave unnoticed remnants in easily accessible areas, such as the Lalouette pyramid. Surgery performed in referral centers and post-surgical cervical ultrasound could help improve long-term outcomes in these patients.

## References:

1. Ross DS, Burch HB, Cooper DS, Greenlee MC, Laurberg P, Maia AL, et al. 2016 American Thyroid Association Guidelines for Diagnosis and Management of Hyperthyroidism and Other Causes of Thyrotoxicosis. *Thyroid*. 2016; 26 (10): 1343-1421.
2. Snook KL, Stalberg PL, Sidhu SB, Sywak MS, Edhouse P, Delbridge L. Recurrence after total thyroidectomy for benign multinodular goiter. *World J Surg*. 2007; 31: 593-598.
3. Lin YS, Lin JD, Hsu CC, Yu MC. The long-term outcomes of thyroid function after subtotal

- thyroidectomy for Graves' hyperthyroidism. *J Surg Res*. 2017; 220: 112-118.
4. Barczyński M, Konturek A, Hubalewska-Dydejczyk A, Gołkowski F, Nowak W. Randomized clinical trial of bilateral subtotal thyroidectomy versus total thyroidectomy for Graves' disease with a 5-year follow-up. *Br J Surg*. 2012; 99 (4): 515-522.
5. Basili G, Andreini R, Romano N, Lorenzetti L, Monzani F, Naccarato G, Goletti O. Recurrence of Graves' disease in thyroglossal duct remnants: relapse after total thyroidectomy. *Thyroid*. 2009; 19(12): 1427-1430
6. Sung TY, Lee YM, Yoon JH, Chung KW, Hong SJ. Long-Term Effect of Surgery in Graves' Disease: 20 Years Experience in a Single Institution. *Int J Endocrinol*. 2015; 2015: 542641.
7. Guo Z, Yu P, Liu Z, Si Y, Jin M. Total thyroidectomy vs bilateral subtotal thyroidectomy in patients with Graves' diseases: a meta-analysis of randomized clinical trials. *Clin Endocrinol (Oxf)*. 2013; 79(5):739-46.
8. Jakibchuk K, Ali S, Samantray J. Recurrence of Graves' disease in ectopic thyroid tissue. *BMJ Case Rep*. 2018; 2018. pii: bcr-2017-221566.
9. Winters R, Christian RC, Sofferman R. Thyrotoxicosis due to ectopic lateral thyroid tissue presenting 5 years after total thyroidectomy. *Endocr Pract*. 2011; 17(1): 70-73.
10. D'Andrea V, Cantisani V, Catania A, Di Matteo FM, Sorrenti S, Greco R, et al. Thyroid tissue remnants after "total thyroidectomy". *G Chir*. 2009; 30(8/9): 339-344.

