



International Journal of Traditional and Complementary Medicine
(ISSN:2474-1361)



Lotus Leaves an Alternate Wound Dressing Material in Chronic Non-Healing Venous Ulcers

Dr. Rajeshwari P. N¹, Dr. Sreejith S. J², Dr. Sharath S.G³

¹Associate Professor, Dept of Shalya Tantra (Surgery), Amrita School of Ayurveda, Amritapuri, Amrita Vishwa Vidyapeetham, India; ²P.G Scholar, Dept of Shalya Tantra (Surgery), Amrita School of Ayurveda, Amritapuri, Amrita Vishwa Vidyapeetham, India; ³Associate Professor, Dept of Rachana Shareeram (Anatomy) Amrita School of Ayurveda, Amritapuri, Amrita Vishwa Vidyapeetham, India

ABSTRACT

It is a case report of 48-year-old male patient of chronic non-healing Venous ulcer. Five ulcers were found on inspection on medial aspect of left foot. Symptoms started as slight discoloration, before 30 years. As days progressed even a small scratch leads to ulcer formation. He managed the condition by taking allopathic medicine and got a satisfactory result. But the discoloration persisted, and the ulcers reoccurred with severe burning sensation and itching. Again, he took homeopathic medication and got symptomatic relief. Due to the recurrence of ulcers, Ayurvedic treatment was started on In-Patient basis followed by both external and internal medications. Externally, patient was treated by Patradaana (a type of wound healing treatment using leaves) with Jathyadi kera tailam (oil Preparation) and internally by Syp. Cardorium plus (Herbal formulation), Sahacharadi Kashaya (Medicated Decoction) and Triphala guggulu (Tablet). Sterile Lotus leaves smeared with Jathyadi kera taila were used for covering the ulcer site and the bandage was retained for 12hrs. Later the ulcer sites were covered with a gauze to avoid exposing to the uncleanness, until the next bandage. The procedure is continued for 8 days. Sahacharadi Kashaya (Medicated Decoction) and Triphala guggulu (Tablet) were advice for a period of 3 weeks and Syrup. Cardorium plus (Herbal formulation) was continued for 2 months. This was an attempt to bring the concepts mentioned in Ayurveda classics for Vrana treatment and got a satisfactory result after following this treatment protocol.

Keywords: Venous Ulcer, Patradaana (a type of wound healing treatment using leaves), Cardorium plus (Herbal formulation)

*Correspondence to Author:

Dr. Rajeshwari P. N

Associate Professor, Dept of Shalya Tantra (Surgery), Amrita School of Ayurveda, Amritapuri, Amrita Vishwa Vidyapeetham, India

How to cite this article:

Dr. Rajeshwari P. N., Sreejith S. J, Sharath S.G. Lotus Leaves an Alternate Wound Dressing Material in Chronic Non-Healing Venous Ulcers .International Journal of Traditional and Complementary Medicine 2018, 3:9.



eSciPub
eSciPub LLC, Houston, TX USA.
Website: <http://escipub.com/>

Introduction

Sushruta, Ancient surgeon consider use of several leaves as wound Dressing material in Chronic Non-healing Ulcers. Lotus leaves are one among them. Recent studies scientifically assessed for the first time the wound healing properties of Banana Leaves with Standard wound dressings in Clinical trials.¹Hence these were proved to be an alternative dressing material easily available in tropical countries at a low cost. Textual reference for the use of Lotus leaves in chronic non-healing ulcer was taken from Sushruta Sahita.

Ulcers of lower part of leg, ankle and foot are common problem faced by surgeons².Among them ulcers which occurs due to venous disease is the most common type and it causes significant pain and burden for the patients. The basic cause of venous ulcer is abnormal venous drainage in the lower third of the leg due to incompetent perforators. Pain expressed as discomfort and swelling over the ankle known to be ankle flair are the major symptoms, along with pigmentation and eczema exists for months or years before a venous ulcer develops. Majority of venous ulcers follow many years of venous disease, so the patients are usually of the age group of 40 to 60 years. The chronicity of the disease goes into the nonhealing ulcer. The site of the ulcer influences the healing process. The site of Venous ulcers in later stages devoid of Circulation due to venous insufficiency, loses its moisture content which primes to nonresponsive status to any local applications. In this phase necessary measure should be taken to retain the moisture content of the wound and enable the process of healing. Also, the medicines which facilitates the venous drainage should be recommended for the early recovery of the patient.

Hence an Ayurvedic wound healing methodology *Patradaana* (a type of wound healing treatment using leaves) explained in Sushruta Samhita was selected and this modality is hardly adopted in clinical practice.

Patradaana is one among 60 modalities for treating Chronic ulcers³. Proper wound healing is not possible in extreme dryness, hardness and in the presence of less skin. *Patradhana* treatment is indicated in Sushruta Samhita mainly for ulcers which doesn't heal due to the above-mentioned features. Sterile Lotus leaves smeared with medicated oil was applied over ulcer site and retained for 12hrs. During procedure patient was administered with Conservative medicines to accelerate the process of healing. This was an attempt to bring the concepts mentioned in Ayurveda texts into practice in Chronic ulcer treatment and got a contented result after following this treatment protocol.

Case Description

A 48-year-old Non-diabetic and Non-hypertensive male patient with code number SHL265 came to In-Patient department of Amrita School of Ayurveda on 19.08.2017 complaining of ulcer over medial malleoli of Left foot associated with burning sensation for 15 days. On inspection five ulcers were found on medial, lateral & dorsal aspect of foot associated with discharge. Also revealed, blackish discoloration of skin with pre-gangrenous changes, swelling around the ankle with small blisters. On Palpation the local area was tender with pitting edema. The onset of the condition is episodic from last 30 years, and he noticed gradual onset of discoloration over both legs. As the days progressed, even a small scratch lead to the formation of ulcer. Cleaning and dressing was done by the patient itself at home, but it didn't give considerable relief. The wound remained chronic with discharge with local pruritis. Conservative medicines alone couldn't give promising result in promoting healing. Ankle flare was worsening the present condition. Hence planned for an In-patient treatment by adopting new methodology for wound healing.

INTERVENTION

The complication of the previous episodes of the condition and its chronicity made the patient to come to In-Patient Department for complete treatment which was planned as follows. As Pre-operational assessment the patient was suggested to undergo routine blood examination. (Blood Routine DC, TC, Hb%, BT, CT, ESR, HIV, HBsAg, Clotting time and Bleeding Time). Majority of the investigations were within normal limits except Raised ESR about 96mm/hr. Doppler Scan imaging of bilateral lower limbs. Arteriography and Venography report of the Bilateral lower limbs showed Venous vein in Both Long saphenous and Short saphenous territories with few incompetent perforators below the knee with Competent Sapheno-femoral Junction. Presently condition is associated with subcutaneous edema around the ankle.

Methodology:

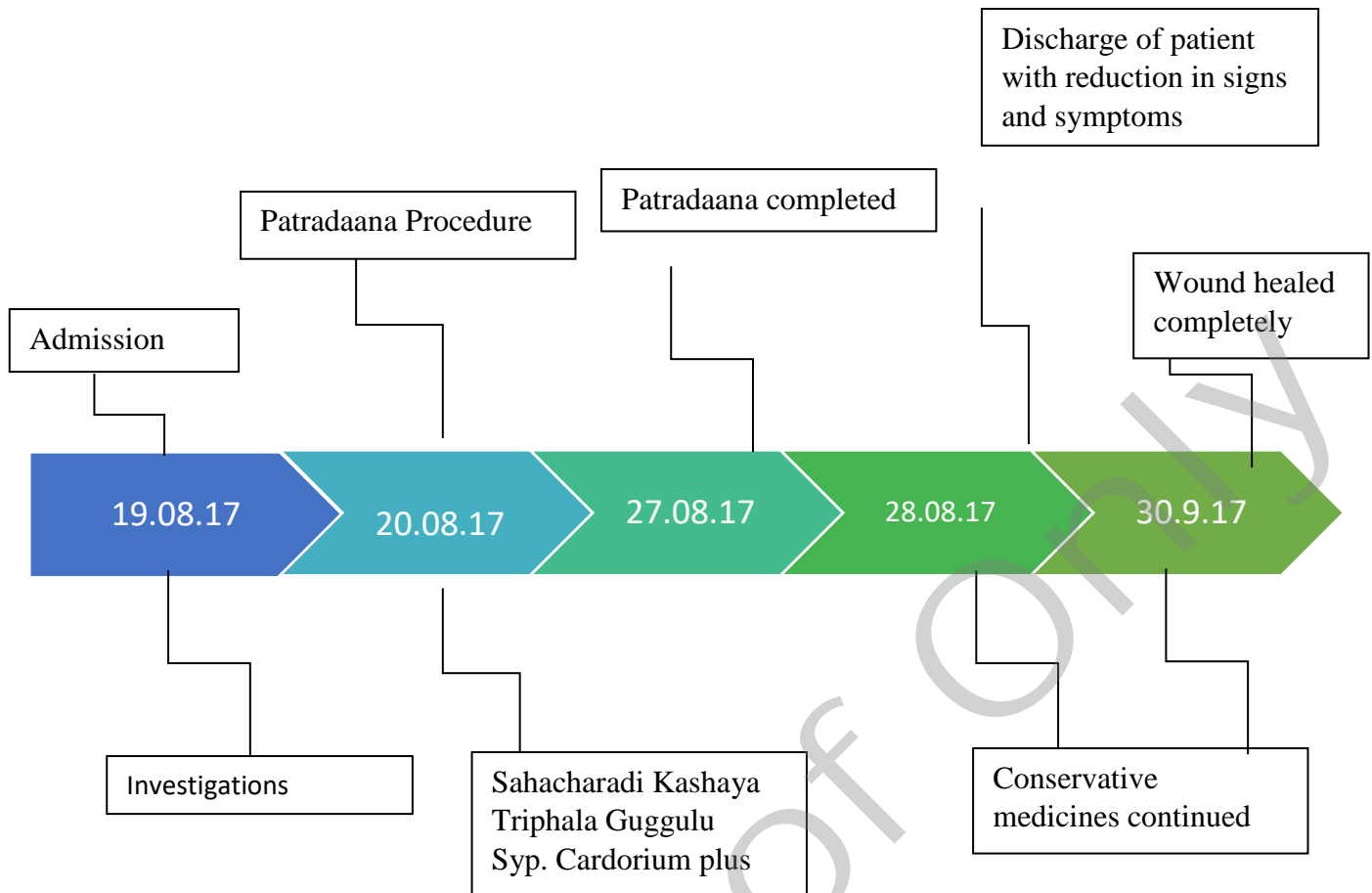
The patients foot was immersed in the decoction of *Triphala*, entire ulcers were cleaned, and the site was draped under aseptic condition. Lotus leaves of the size 14cmX20cm is trimmed and taken from whole leaf. The ridges of the leaf are removed to provide a

uniform surface. The leaves are dipped in boiling water to inactivate the bacterial flora and make it suitable for dressing. Boiling in water is sufficient to remove bacterial load and renders them suitable for use on surgical wounds¹. The smooth surface of the leaf is smeared with *Jathyadi Kera taila* and wrapped around the leg covering all the ulcers. The leaves are held in situ with a gauze bandage and retained for 4hrs. Bandage is removed after 4hrs, excessive oil is wiped off from the wound surface and covered with a sterile gauze pad until the next bandage. *Sahacharadi Kashaya* (Medicated Decoction) 20ml diluted with 40ml of water TID and *Triphala guggulu* (Tablet) one tablet TID were advised for a period of 3weeks. Syrup. Cardorium plus (Herbal formulation) was continued for 2months.

Cleaning was done with *Triphala* decoction and dressing with Lotus leaf was done systematically for 8days. On 28/04/17 patient was examined, and wound was healing with Healthy granulation tissue formation. Patient got considerable relief from swelling, itching and discharge.

Table 1: Showing Clinical Findings During Patradana

DATE	DISCHARGE	ITCHING	TENDERNESS
20.08.17	+++	++	+++
21.08.17	+++	+	+++
22.08.17	++	+	+
23.08.17	+	+	+
24.08.17	+	+	+
25.08.17	+	+	+
26.08.17	+	-	+
27.08.17	+	+	+

Table 2: Timeline Showing Treatment Schedule of The Patient.

OBSERVATIONS AND RESULT

Venous ulcers are usually recurrent and can persist for weeks to many years. Severe complications include cellulitis, osteomyelitis, and malignant change. Poor prognostic factors include large ulcer size and prolonged duration for healing. The new modality of wound dressing decreased excessive oozing from the wound site and promoted the process of wound healing. The approximate wound contraction was 1cm in a week with formation of healthy granulation tissue over the surface of wound. The pain, itching and ankle flare considerably relieved with reduction in tenderness of local area. The combined effect of internal medication and an External treatment gave promising result to the patient

Discussion

Venous ulcers are the wounds occurring due to incompetent venous valves of lower limbs. It is one of the most chronic venous insufficiency

complications. When a venous valve gets damaged, it prevents the backflow of blood, which causes pressure in the veins that leads to hypertension and leads to venous ulcers. Ulcers are along the medial distal leg, which is often very painful, can bleed, and get infected. Treating Venous ulcers is a difficult job to the surgeons, despite a good number of the treatment principles are mentioned and practiced in allied sciences. Probable causes of venous ulcers include inflammatory processes resulting in leukocyte activation, endothelial damage, platelet aggregation, and intracellular edema. The primary risk factors for venous ulcer development are older age, obesity, previous leg injuries, deep venous thrombosis, and phlebitis⁴. Granulation tissue and fibrin are the components of ulcer base. Associated results include varicosity of lowerlimb, edema, dermatitis or eczematous changes, and lipodermatosclerosis. Evidence-based treatment choices for venous ulcers include leg

elevation, compression therapy, dressings, pentoxifylline, and aspirin therapy. For a healthy and faster wound healing appropriate wound dressing is necessary. An Ideal wound dressing should combine the following features like a moist environment at the wound scene, a barrier function to microorganisms and non-adherent, nontoxic, non-allergenic, non-sensitizing¹. Modern wound dressing possesses all these qualities, but it is very expensive when it is used for long time. Lotus leaves can possess all these properties along with less consequences. Lotus is an aquatic plant since its leaves can provide moisture at wound site along with all the above-mentioned properties it helps in faster wound healing. In this case within short period of time Rapid epithelization occurred after *Patradana* along with *Jathyadi kera taila*, followed by internal medications.

Conclusion

Now a day treating an ulcer is one of the greater challenges faced by all the surgeons. It

is because of lack of appropriate wound dressing measures which is very much needed in wound healing. The limitation increases in conditions like Venous ulcer. Lotus leaves provides a healthy platform for proper and faster wound healing. Also, it is very much cheaper than collagen or biosynthetic dressings. Hence with the help of both external and internal medications a case of chronic Venous ulcer was successfully treated within a short period of time.

REFERENCES

1. *Banana leaves: an alternative wound dressing material*. Wolfram Hoetzenecker, Emmanuella Guenova and Matthias Moehrie. Switzerland, Germany : Expert Reviews, 2014.
2. Das, Somen. *A Manual on Clinincal Surgery*. Calcutta : Dr.S.Das, 2004.
3. Acharya, Vaidya Jadvji Trikamji. *Susruta samhita*. Pune : Chaukhambha Sanskrit sansthan, 2013.
4. An integrated approach in the treatment of varicose ulcer: PMC3902537/2013

